

Journal of CONTACT LENS RESEARCH & SCIENCE

Proceedings of the International Forum on Scleral Lens Research

WAVEFRONT-GUIDED CONTACT LENS CORRECTIONS – INCREASING CHOICE FOR THE INDIVIDUAL WITH KERATOCONUS

Jason D. Marsack and Raymond A. Applegate

THE PERSPECTIVE OF THE INDIVIDUAL WITH KERATOCONUS

If one were to ask an individual with keratoconus what need they hope to meet with an optical correction, the response would be as varied as the number of individuals diagnosed with the disease. Keratoconus impacts individual patients in myriad ways, and different aspects (or dimensions) of the correction are important to each individual patient. From our work in the laboratory, several recurring, and at times competing, dimensions have come to the forefront. For example, visual and optical performance may be of the utmost importance for one patient, while comfort and an ability to wear the lenses for the majority of waking hours may be paramount for another. Given that no single correction can meet the needs of every individual with keratoconus (just as no single correction can meet the needs of the typical population) a pressing need in regards to optical correction for the individual with keratoconus can be summarized in two words: *increased choice*.

THE CURRENT STATE OF CORRECTION


Historically, the most common form of contact lens for individuals with keratoconus has been some form of rigid contact lens correction.¹ Additional choice has more recently become available with the resurgence in scleral contact lens fitting, which is also a rigid form of correction. These corrections reduce irregular astigmatism (or by its visual optics

name: higher order aberration). But whether we are discussing a conventional rigid corneal lens or a conventional scleral lens, higher order aberration is not targeted on an individual patient basis. The result is that these corrections may leave individuals with keratoconus with less-than-optimal optical and visual performance. Studies in both corneal and scleral lenses have shown elevated levels of higher order aberration remain present during correction.²⁻⁹

THE IMPACT ON THE PRACTITIONER AND PATIENT

It is not only the patient that is impacted by elevated levels of higher order aberration. Practitioners can be left in the unenviable position of not being able to meet the needs of their most difficult patients. For example, every clinician that treats individuals with keratoconus will be familiar with the patient that achieves 20/20 vision but remains unsatisfied. Perhaps they refer to the presence of “ghosting” or “shadows” or “doubling of letters” or “starbursts at night.” This might at first seem counter-intuitive; how is it possible that someone can achieve such excellent visual acuity and remain unsatisfied? The reason stems from the fact that visual acuity reports quantity of vision (how far can you read down on the letter chart?), not quality of vision (how sharp do the letters on this chart appear?). For instance, look at the letter chart shown in Figure 1, which shows the resulting simulated retinal image constructed from the measured wavefront error of

FIG. 1 Simulated retinal image constructed from the measured wavefront error of an individual with keratoconus that was corrected by a traditional scleral contact lens. Note that while the most lines on the acuity chart are legible, ghosting and reduced contrast are present. The single bar indicates the 20/20 line.



an individual with keratoconus that was wearing a traditional scleral contact lens. This image simulates what the image of the letter chart will look like on the retina of this individual patient.

The retinal image quality through this lens remains degraded due to the presence of elevated levels of aberration. While the vision afforded by this contact lens is no doubt superior to vision that this individual will achieve without correction, there remains room for optical and visual improvement.

Or, to return to our original premise: this patient needs additional choices to meet their optical needs.

INDIVIDUALIZED CORRECTION WITH WAVEFRONT-GUIDED CONTACT LENSES

One such additional choice that has been the topic of much enthusiasm is the wavefront-guided contact lens. This form of correction integrates a quantitative measure of the uncorrected optical error (both lower and higher order aberration) of an individual wearing a conventional correction, thereby targeting these residual aberrations on a patient-by-patient basis.

For example, when the residual uncorrected aberration measured through the conventional scleral contact lens shown in Figure 1 was measured and

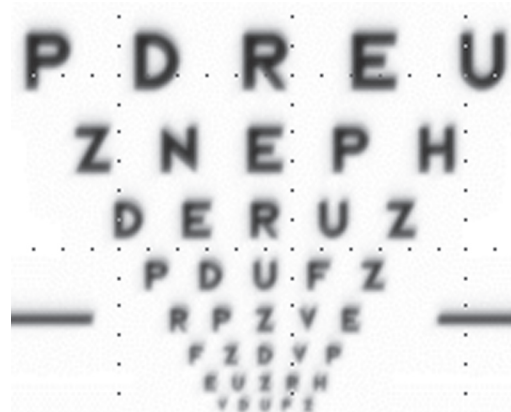designed into a subsequent wavefront-guided scleral contact lens for the same individual, the improvement in simulated retinal image quality is marked. Figure 2 below shows the resulting simulated retinal image for the same eye pictured in Figure 1, but in this case wearing the wavefront-guided scleral lens.

Comparison of the 20/20 lines from both Figure 1 and Figure 2 shows that both contain relatively sharp edges on the letters, however the letters in Figure 1 have reduced contrast and are surrounded by more ghosting. In such a case, a patient may be able to read both 20/20 lines but may continue to report complaints regarding the quality (not quantity) of their vision. Put simply, in this case the wavefront-guided lens provides better retinal image quality.

THE EMERGENCE OF WAVEFRONT-GUIDED LENSES

The topic of wavefront-guided lenses has been under intense discussion for at least a decade and was the focus of a session at The 2nd Annual International Forum for Scleral Lens Research. The session focused on the potential benefit as well as the practical challenges associated with wavefront-guided contact lens corrections from several different points of view. These include the perspective of the contact lens manufacturer,

FIG. 2 Simulated retinal image for the same subject pictured in Figure 1. In this case, the individual is wearing a wavefront-guided scleral contact lens designed to target their specific levels of ocular aberration. The single bar indicates the 20/20 line.



the academic clinician, the private practice clinician, the scientist/engineer and the patient. Questions raised included the potential benefit of these corrections, more theoretical questions related to design limitations, delivery methods as well as discussion of successful demonstrations (both laboratory and practice-based) of wavefront-guided contact lenses for individuals with keratoconus.

SUMMARY

Again, returning to the original premise of this article, it is our hope that as a collective group we continue to ask the question “How can we continue to increase choice to meet the needs of a widening segment of the keratoconus population?” When considering optical and visual performance for individuals that are impacted by keratoconus, one such choice is the wavefront-guided contact lens, which is an excellent example of individualized medicine tailored to the individual needs of the patient.

REFERENCES

1. Zadnik K, Barr JT, Edrington TB, et al. Baseline findings in the Collaborative Longitudinal Evaluation of Keratoconus (CLEK) Study. *Invest Ophthalmol Vis Sci* 1998;39:2537–46.
2. Kosaki R, Maeda N, Bessho K, et al. Magnitude and orientation of Zernike terms in patients with keratoconus. *Invest Ophthalmol Vis Sci* 2007;48:3062–8.
3. Negishi K, Kumanomido T, Utsumi Y, Tsubota K. Effect of higher-order aberrations on visual function in keratoconic eyes with a rigid gas permeable contact lens. *Am J Ophthalmol* 2007;144:924–9.
4. Marsack JD, Parker KE, Pesudovs K, Donnelly WJ 3rd, Applegate RA. Uncorrected wavefront error and visual performance during RGP wear in keratoconus. *Optom Vis Sci*. 2007;84:463-70.
5. Salmon TO, van de Pol C. Normal-eye Zernike coefficients and root-mean-square wavefront errors. *J Cataract Refract Surg*. 2006;32:2064–74.
6. Applegate RA, Donnelly WJ 3rd, Marsack JD, et al. Three-dimensional relationship between high-order root-mean-square wavefront error, pupil diameter, and aging. *J Opt Soc Am A Opt Image Sci Vis* 2007;24:578–87.
7. Gumus K, Gire A, Pflugfelder SC. The impact of the Boston ocular surface prosthesis on wavefront higher-order aberrations. *Am J Ophthalmol* 2011;151:682–90.
8. Sabesan R, Johns L, Tomashevskaya O, et al. Wavefront-guided scleral lens prosthetic device for keratoconus. *Optom Vis Sci* 2013;90:314–23.
9. Marsack JD, Ravikumar A, Nguyen C, et al. Wavefront-guided scleral lens correction in keratoconus. *Optom Vis Sci* 2014;91:1221–30.